

# The edge-to-edge technique for mitral valve repair

M. De Bonis, O. Alfieri

*Department of Cardiac Surgery, Università Vita-Salute San Raffaele, Milan, Italy*

## ABSTRACT

The edge-to-edge technique was introduced in the surgical armamentarium of mitral valve repair in 1991 and has progressively been used to restore mitral competence in the setting of degenerative, post-endocarditis and functional mitral regurgitation. Appropriate indications and awareness of the important technical aspects of the procedure are prerequisites for a good outcome. The free edges of the mitral leaflets have to be approximated in correspondence of the site of the regurgitant jet in such a way that mitral regurgitation is corrected without producing stenosis. A prosthetic ring is usually implanted to stabilize the repair. Middle and long-term results are now available for degenerative mitral regurgitation (bileaflet prolapse, anterior leaflet prolapse and commissural prolapse). Of particular interest is the finding that the edge-to-edge technique for correction of anterior leaflet prolapse is providing a freedom from reoperation similar to that obtained in patients with posterior leaflet prolapse treated with quadrangular resection. Degenerative or post-endocarditis commissural prolapse/flail of the mitral valve can be effectively corrected by this technique. In patients with functional mitral regurgitation, the use of the edge-to-edge repair, added to the undersized annuloplasty, has been associated with a significantly lower recurrence of mitral regurgitation in the follow-up compared to isolated undersized annuloplasty. Almost 20 years after its introduction, the edge-to-edge technique remains an effective and versatile method to treat mitral regurgitation. Its simplicity and reproducibility have led to its clinical application by percutaneous methods opening a new age in the fascinating field of reconstructive mitral valve surgery.

**Keywords:** *cardiac surgery, mitral surgery, mitral repair, edge to edge.*

## INTRODUCTION

Degenerative mitral valve disease represents the main cause of mitral regurgitation (MR) in the western countries. Mitral valve repair has become the treatment of choice of degenerative MR because of its well known advantages compared to mitral valve replacement (1, 2). The repair techniques introduced and popularized by Carpentier and coworkers have provided predictable and durable long-term results. The most favourable outcomes have been described in patients with isolated prolapse

of the posterior leaflet treated by a simple quadrangular resection and annuloplasty. On the other hand, less gratifying results have been associated with correction of mitral regurgitation due to anterior, bileaflet or commissural prolapse (3-6). All the Carpentier's techniques for mitral valve repair have been developed to realize an anatomical reconstruction of the diseased mitral valve. However, to reach this goal, they can be technically demanding and time consuming, particularly in the setting of anterior, bileaflet and commissural lesions. An alternative approach to the regurgitant degenerative mitral valve has been introduced by our group in 1991 and has been named "edge-to-edge" technique. The "revolutionary" idea standing behind this new surgical approach is that the competence of a

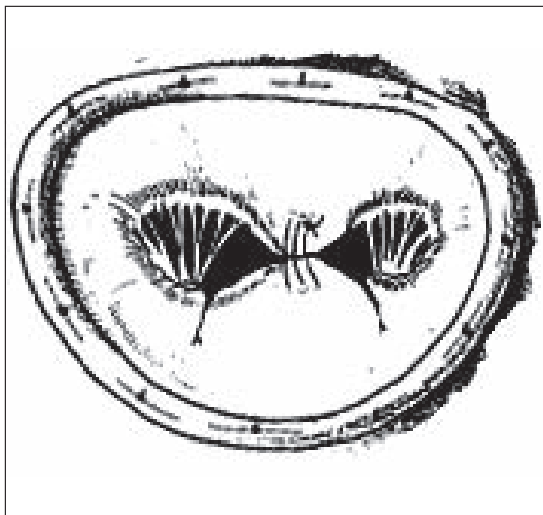
*Corresponding author:*  
 De Bonis Michele, MD  
 Department of Cardiac Surgery  
 San Raffaele University Hospital  
 Via Olgettina 60 - 20132 Milan, Italy  
 e.mail: debonis.michele@hsr.it

2

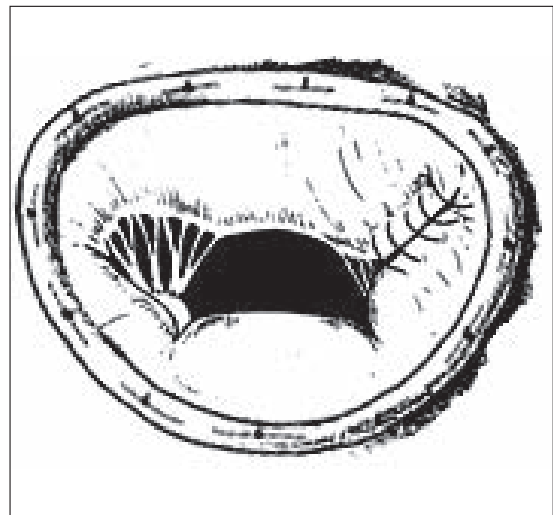
regurgitant mitral valve can be effectively restored with a “functional” rather than an anatomical repair. The key point of this surgical method is to identify with accuracy where the regurgitant jet is located. Exactly at this level the free edge of the diseased leaflet is sutured to the corresponding edge of the opposing leaflet thereby eliminating the mitral incompetence. When the regurgitant jet is in the central part of the mitral valve, the application of the edge-to-edge technique produces a mitral valve with a double orifice configuration (double orifice repair) (*Figure 1*). Depending on the extension and location of the suture performed, the two orifices can have similar or significantly different sizes. In case of commissural prolapse or flail, on the other hand, the jet of regurgitation is usually identified in correspondence of the commissural area. Under these circumstances, the application of the edge-to-edge technique is usually called “paracommissural edge-to-edge repair” and leads to a single orifice mitral valve with a relatively smaller area (*Figure 2*). In many situations, the regurgitant jet

of the mitral valve is not a single one. Particularly in the setting of Barlow’s disease with severe bileaflet prolapse, for example, multiple regurgitant jets are usually found along the entire line of coaptation of the anterior and posterior leaflet. In this case, the edge-to-edge approximation of the middle scallop of the anterior and posterior leaflet (A2 and P2) allows the elimination of most of the mitral insufficiency while the residual smaller regurgitant jets are effectively corrected by the association of a ring annuloplasty.

The first edge-to-edge repair case was performed in 1991 and more than 1500 published cases have been accumulated worldwide so far with the longest follow-up being now longer than 15 years. The technique is attractive because of its simplicity, reproducibility and effectiveness in different settings. Indeed, due to its versatility, the edge-to-edge technique has been used for correction of mitral regurgitation due to different etiologies and mechanisms including bileaflet prolapse (Barlow’s disease), anterior leaflet prolapse, commissural prolapse,



**Figure 1**  
*The edge-to-edge technique used as a double orifice repair.*

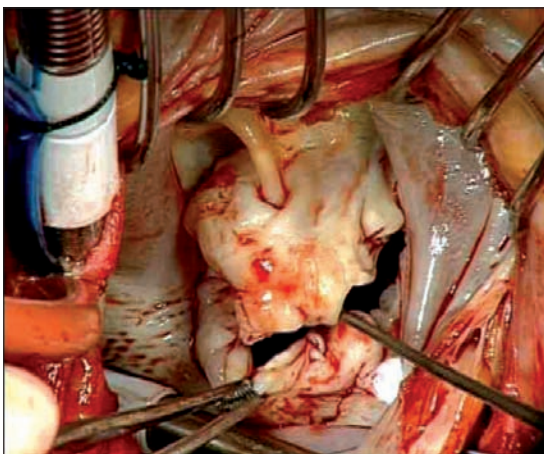


**Figure 2**  
*The edge-to-edge technique used as a paracommissural repair.*

functional mitral regurgitation secondary to ischemic or idiopathic dilated cardiomyopathy. Moreover it has been adopted as a rescue procedure in case of suboptimal result of conventional mitral repair operation and to prevent or treat systolic anterior motion of the anterior leaflet.

#### ***The edge-to-edge technique for bileaflet prolapse in Barlow's disease***

In patients with Barlow's disease, all the components of the mitral valve apparatus are affected by a severe myxomatous degeneration which leads to generalized bileaflet prolapse, severe annular dilatation and severe mitral insufficiency. Doppler echocardiography usually shows diffuse prolapse of most of the anterior and posterior leaflets with multiple jets of regurgitation along the entire coaptation line. Intraoperative inspection demonstrates large, redundant leaflets with irregular free edges and an increased number of clefts (*Figure 3*). Such a generalized disease can certainly be effectively treated by performing an anatomical reconstruction of the mitral valve at annu-



**Figure 3**  
*Intraoperative view of a mitral valve affected by Barlow's disease with important redundancy of all the valve tissue, multiple scallops, chordal elongation and severe bileaflet prolapse.*

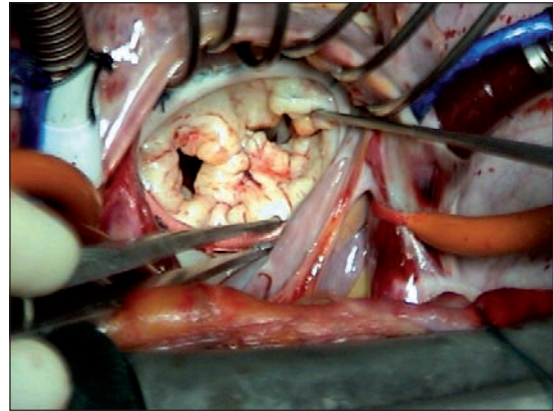
lar, valvular and subvalvular level. However a rather complex operation requiring a long aortic cross-clamp time is usually required. The advantage of using the edge-to-edge approach in this challenging setting is that, with a single and standardized surgical act, it is possible to correct the multiple anatomical defects typically present in Barlow's disease. Indeed, just by suturing the middle scallop of the anterior and posterior leaflet (A2 to P2) followed by ring annuloplasty, the edge-to-edge technique restores valve competence. The edge-to-edge suture is able to correct leaflets' redundancy and prolapse and to prevent post-operative SAM.

#### ***Surgical technique***

The edge-to-edge repair is carried out through a conventional median sternotomy or, in selected patients, through a small right anterior thoracotomy. Following aortic and bicaval cannulation, in normothermic cardiopulmonary by-pass, the aorta is clamped and intermittent cold-blood cardioplegia is delivered into the ascending aorta to obtain cardioplegic arrest. The mitral valve is usually approached through the left atrium after careful dissection of the interatrial groove. In Barlow's disease the mitral annulus is severely dilated and the leaflets are affected by severe myxomatous degeneration. In most of the cases, the entire valve is prolapsing. The segments with the most extensive pathologic involvement, however, are the middle scallops of the anterior and posterior leaflets (A2 and P2). Chordal elongation and rupture are very common and may be responsible for multiple prolapses or flailing lesions. Some important technical aspects have to be considered for a good outcome. The first step is to identify exactly the middle of the anterior and posterior leaflets by inspecting the subvalvular apparatus. The first stitch of the edge-to-edge suture has to be positioned exactly in correspondence of this anatomical middle

4

of the two leaflets. This step is very important to avoid valve distortion and residual valve regurgitation. To be sure of this technical point, the symmetry of the two orifices created is immediately checked. If the correct position of the stitch is confirmed, a continuous mattress suture of 4-0 polypropylene is passed along the whole length of the middle scallop of the anterior and posterior leaflets (A2 and P2) in correspondence of the rough zone. A second over-and-over continuous suture is then added to stabilize the repair. In Barlow's disease the bites have to be rather deep, usually around 1 cm, to reduce as much as possible the height of the redundant leaflets. Usually a wide suture, connecting the whole P2 free edge to the opposing A2, is necessary. When a flail segment is present, this has to be included in the edge-to-edge suture. Therefore the position of the stitch, in this circumstance, may be somewhat asymmetric, corresponding to the center of the flail portion of the leaflet. In this case the size of the two orifices will be different, one being larger than the other one. Such an event should not raise any concern as far as both of them are competent and the sum of their areas is above 2.5 cm<sup>2</sup> for a normal size patient. A flexible or semirigid ring annuloplasty is always added to complete and stabilize the repair (*Figure 4*). Once ring implantation has been completed, the final competence of the two mitral orifices is evaluated by forceful saline filling of the left ventricle. The residual mitral area is assessed by direct inspection and, in case of doubts, Hegar valve dilators can be introduced into the orifices to be sure that a global valve area of at least 2.5 cm<sup>2</sup> in normal size patients has been left. Transesophageal echo-Doppler reassessment of the valve is routinely performed after weaning from cardiopulmonary by-pass. Typically no residual mitral regurgitation is present and two diastolic flows can be visualized through the double orifice mitral



**Figure 4**

*Intraoperative view of a double orifice edge-to-edge repair.*

valve. The valve area is commonly assessed by a planimetric method using the transgastric, short-axis view. Doppler methods can be used as well. The simplicity of the edge-to-edge technique makes it possible to repair complex mitral valves with a cross-clamp time which, in our experience, has been  $33 \pm 3.9$  minutes.

## RESULTS

Our experience with the edge-to-edge technique for the surgical treatment of bileaflet prolapse in the context of Barlow's disease includes 648 consecutive patients submitted to mitral valve repair from 1991 to March 2008. Hospital mortality was 0.92% (6/648). Actuarial survival at 5 years was  $92\% \pm 4.5\%$  and freedom from reoperation  $91\% \pm 4.2\%$  with no patients requiring late reoperation for mitral valve stenosis. Echocardiographic follow-ups show good results of the repair, with stable competence and no progression of valve stenosis: the mean mitral valve area, assessed in a subgroup of 75 patients, was  $10.2 \pm 2.1$  cm<sup>2</sup> preoperatively, decreased to  $3.7 \pm 0.8$  cm<sup>2</sup> after repair and did not significantly

change at a mean follow-up of 1.3 years (113 patient-years, range 1 month-5 years) remaining  $3.6 \pm 0.97 \text{ cm}^2$  (7). Considering the unfavorable anatomical features and the complexity of the mitral valve lesions of patients affected by Barlow's disease, we consider these results very satisfactory.

### ***The edge-to-edge technique for anterior leaflet prolapse***

We have analyzed and reported the late outcome of a series of 133 patients with segmental prolapse of the anterior leaflet submitted to isolated edge-to-edge repair and mitral annuloplasty over a period of 10 years (8). No hospital deaths occurred and long-term (up to 13 years) clinical and echocardiographic follow-up was 100% complete. Overall 10 year survival was  $91 \pm 4.06\%$ , freedom from cardiac death  $95.8 \pm 2.83\%$  and freedom from reoperation  $96 \pm 2.3\%$  with 93.2% of the patients being in NYHA functional class I or II at a mean follow-up of  $4.5 \pm 3.12$  years (range 1 month-13.2 years). The mean mitral valve area after repair was  $2.6 \pm 0.6 \text{ cm}^2$  (range 2-4  $\text{cm}^2$ ) and the mean mitral gradient  $3.1 \pm 1.5 \text{ mmHg}$  (range 1.8-5.8 mmHg). Mitral stenosis was never detected immediately after surgery or later and, at the last follow-up, mitral regurgitation was absent or mild in 120 patients (90.1%), moderate in 10 patients (7.5%) and severe in 3 patients (2.2%). All these 3 patients were reoperated. These results were comparable to those obtained in our Institution with patients submitted to standard quadrangular resection for prolapse of the posterior leaflet which means that, in our experience, the edge-to-edge repair has been able to neutralize the prolapse of the anterior mitral leaflet as an incremental risk factor for suboptimal results in mitral valve repair. These results were obtained in patients with segmental prolapse of the anterior leaflet, involving only one scallop. On the other hand, in presence of an

extended anterior leaflet prolapse, involving more than one scallop, the edge-to-edge technique alone may not be sufficient to obtain a perfectly competent valve since a long suture would be required with higher risk of inducing mitral stenosis. Under the above circumstances, the implantation of artificial chordae may be required in order to eliminate incompetence without excessively reducing the mitral valve area.

### ***The edge-to-edge technique for commissural prolapse***

Mitral valve repair in patients with commissural lesions can be very challenging with conventional techniques. The edge-to-edge technique associated to annuloplasty can enable a rapid and reliable mitral reconstruction and may be applied to correct either one or both leaflet prolapses/flails at the commissure. In the Cleveland Clinic experience, more than 100 patients with commissural prolapse/flail have been treated with suture closure of the commissure, with no instances of mitral stenosis, suture dehiscence or recurrent prolapse in the follow-up (9). In our opinion, commissural edge-to-edge repair associated to annuloplasty is probably the simplest and most reproducible method to repair commissural lesions. We have employed this technique for approximation of the mitral valve leaflets at the commissural area in 115 patients for managing isolated commissural prolapse or flail. The clinical and echocardiographic results have been very satisfactory (10). The incidence of reoperation has been very low (2 out of 114 hospital survivors, 1.7%). An echocardiographic follow-up was performed in 108 patients (all with severe preoperative MR) at a mean postoperative time of  $2.3 \pm 1.9$  years (median 2.0 years, range 1-8.3 years). Mitral regurgitation was absent in 60 patients (55.6%), mild in 43 (39.8%), moderate in three (2.8%) and severe in two (1.9%, both reoperated on). No instance of

mitral stenosis was ever documented as indicated by the low transvalvular gradients recorded echocardiographically. The longest follow-up is now approaching nine years and the satisfactory echocardiographic data obtained so far are certainly encouraging a strategy of early mitral repair also in the difficult setting of commissural mitral valve incompetence. Because of its excellent clinical and echocardiographic result, it remains the method of choice to correct isolated commissural prolapse or flail at our Institution.

***The edge-to-edge technique for functional mitral regurgitation in dilated cardiomyopathy***

Mitral regurgitation is regarded as secondary (or functional) when the valve leaflets and chordae are structurally normal and the valve dysfunction is due to altered ventricular shape and dimension (remodelling) with displacement of one or both papillary muscles. Tethering of the leaflets is the main mechanism responsible for secondary MR. Annular dilatation is often concomitantly present, particularly when the valve insufficiency is severe and long-standing and the left ventricle is remarkably dilated.

Undersized annuloplasty (at least two sizes under) using a complete rigid ring is the standard operation, effective in most cases. To enhance the likelihood of a successful and durable repair, other procedures have been proposed to be added to annuloplasty including the edge-to-edge repair. In regard to the latter technique, the Cleveland Clinic group reported a disappointing 24% recurrence rate of moderately-severe (3+) mitral regurgitation 2 years after edge-to-edge repair of functional mitral regurgitation (11). These results, however, can mainly be explained by the fact that, in that series, the edge-to-edge technique was always employed in association with a posterior flexible band, which may not prevent the recurrence of annular dilatation in the setting of advanced

dilated cardiomyopathy. Indeed, the patients requiring reoperation almost invariably presented re-dilatation of the mitral annulus. In our Institution the “edge-to-edge” was associated to an undersized annuloplasty whenever substantial apical tenting was present (coaptation depth > 1 cm). However, from a technical point of view, the concomitant annuloplasty was always performed with a complete rigid or semirigid ring and the site of leaflet approximation was literally guided by the echocardiographic findings. This approach significantly increased the durability of mitral repair in our series with a freedom from failure at 1.5 years of  $95\% \pm 3.4\%$  compared to  $77 \pm 12.1\%$  registered in those patients submitted to isolated undersized annuloplasty in our department in the same time frame ( $p = 0.04$ ) (12). Moreover, in this same study, the use of the edge-to-edge technique was identified as the only significant predictor of durability of the repair, which confirms the role of this technique in this challenging setting.

***Rescue “edge-to-edge”***

The “edge-to-edge” technique has also been used as a “rescue” procedure in patients with significant residual mitral regurgitant after conventional mitral repair. Gatti and coworkers reported the adoption of this strategy in 11 patients (13). At intraoperative ecocardiography, residual mitral regurgitation improved from  $3.0 \pm 0.8 \text{ cm}^2$ , after conventional repair, to  $0.7 \pm 0.9 \text{ cm}^2$  after rescue “edge-to-edge” ( $p = 0.00014$ ). The original reconstruction was not taken down and the additional cardiopulmonary bypass time was only  $14.9 \pm 2.8 \text{ min}$ . These echocardiographic results were confirmed at a follow-up of  $13.8 \pm 8.1 \text{ months}$ . The “edge-to-edge” suture was just added in correspondence of the site of the regurgitant jet according to the echo findings. Other Authors, however, have reported suboptimal results with the edge-to-edge used to

treat residual regurgitation after complex mitral repair (14). Indeed, in this context, the efficacy of the “edge-to-edge” repair is very difficult to predict considering that it should be able to restore the mitral valve competence after a failed conventional repair. Moreover, particularly if the first surgery included a resection procedure, the shortest edge-to-edge suture should be applied to avoid the risk of mitral stenosis.

***The “edge-to-edge” technique to prevent or treat systolic anterior motion (SAM)***

Systolic anterior motion (SAM) of the anterior mitral leaflet causing left ventricular outflow tract obstruction remains one of the most common complications after mitral valve repair. It has been postulated that use of the edge-to-edge technique might be effective to prevent or treat SAM occurring after mitral repair. Mascagni and colleagues reported the use of the edge-to-edge technique to prevent post-repair SAM in four patients (15). More recently Brinster and coworkers (14) adopted the edge-to-edge repair with this purpose in twenty patients submitted to mitral valve reconstruction. In all cases SAM was completely eliminated and the mean MR grade in the immediate postoperative period was  $0.5 \pm 0.7$ . No patient developed mitral stenosis and none developed SAM or progressive MR at follow-up. The freedom from reoperation at 4 years was 100%. Also the Cleveland Clinic reported on the use of the edge-to-edge technique for the treatment of SAM. In particular Bhudia and coworkers (11) described the application of the edge-to-edge to lessen the likelihood of SAM in patients with hypertrophic obstructive cardiomyopathy (HOCM) submitted to myectomy. Elimination of SAM was achieved in the 14 patients treated although systolic anterior motion could still be demonstrated occasionally due to displacement of the lateral portion of the anterior leaflet which had not been fixed to the

posterior leaflet by the edge-to-edge suture which had been placed in the central part of the mitral valve. Although further studies are required, the edge-to-edge seems to have a role in eliminating SAM post-repair or in preventing the occurrence of systolic anterior motion in patients with pre-repair echocardiographic predictors of SAM.

***The minimally invasive approach option***

In patients with severe degenerative mitral regurgitation an early surgery policy is recommended whenever a very high probability of repair can be ensured. Those patients are usually young, asymptomatic, with good LV function and no significant comorbidities. Therefore they are ideal candidates for a minimally invasive mitral repair operation performed through a small right thoracotomy. The edge-to-edge technique, because of its technical simplicity and reproducibility, can be easily applied through such an approach. From a technical point of view patients are intubated with a double-lumen endotracheal tube and a 14 F cannula is placed percutaneously through the right jugular vein into the superior vena cava. A 6 to 8-cm minithoracotomy is then performed through the fourth intercostal space and a soft tissue retractor is used for spreading the ribs. One port is created laterally to the incision to introduce both a 5 mm video scope and a CO<sub>2</sub> line to flush the operative field. Pericardial stay sutures are passed through and fixed out of the chest. Following cannulation of the femoral vessels, cardiopulmonary bypass (CPB) is established between femoral artery and femoral and jugular veins, at 28–30°C. Aortic cross-clamp is performed by using the Chitwood transthoracic clamp inserted through the second or third intercostal space and intermittent antegrade cardioplegia is delivered through an aortic root catheter. The mitral valve is exposed in all cases through a left atriotomy using a transthoracic atrial retractor posi-

tioned in the fourth intercostal space. The valve is analyzed and repaired by direct vision through the minithoracotomy incision. Whenever the view is suboptimal, the inserted camera is used to improve valve assessment and reconstruction. Long-shafted Heartport instruments, passed through the minithoracotomy, are used. Even complex degenerative mitral disease can be effectively corrected through such a right minithoracotomy by using the edge-to-edge technique. In our experience this minimally invasive strategy did not compromise the durability of repair providing a very high patient satisfaction in terms of cosmetic results, postoperative pain and time to full recovery after the operation (16).

#### ***Edge-to-edge repair and annuloplasty***

A concomitant annuloplasty represents a key factor for the long-term durability of the edge-to-edge repair. Indeed, in absence of annuloplasty, further dilatation of the mitral annulus can take place after surgery leading to recurrent MR. Although at the beginning of our experience the edge-to-edge technique has been adopted in some cases without an associated annuloplasty, today we recommend to add always an annuloplasty to the edge-to-edge repair, if technically feasible, to increase the coaptation surface of the leaflets, enhance the competence of the valve, reduce the stress on the edge-to-edge suture and prevent the possibility of subsequent annular dilatation. We have been able to demonstrate that the lack of annuloplasty is one of the most important factors of edge-to-edge repair failure with a freedom from reoperation at 5 years which decreases from 92% in patients with annuloplasty to 79% in those without (17).

#### ***Double orifice edge-to-edge repair and hemodynamics***

When the edge-to-edge technique is adopted as a double orifice repair, the mor-

phology of the mitral valve becomes that of a valve with two orifices. Which are the possible hemodynamic effects of such an unusual configuration? This question was formulated since the introduction of this new technique and addressed by performing computational model studies which demonstrated that the hemodynamic performance of a double-orifice mitral valve depends exclusively on the total valve area and on the cardiac output (18) and not on the double orifice shape. In double-orifice valve configuration, the velocity of the flow through each orifice is very similar to the one observed through a single orifice valve of area equal to the sum of the areas of the two orifices. Moreover the flow velocities through the two orifices are exactly the same, even when the orifice sizes are significantly different, which means that the Doppler sampling of any of the two orifices is sufficient to assess the hemodynamic of the mitral valve. Indeed, in our clinical practice, patients previously submitted to double orifice repair demonstrated at Doppler examination blood flow velocities comparable in the two orifices.

#### ***Edge-to-edge repair and the risk of functional mitral stenosis***

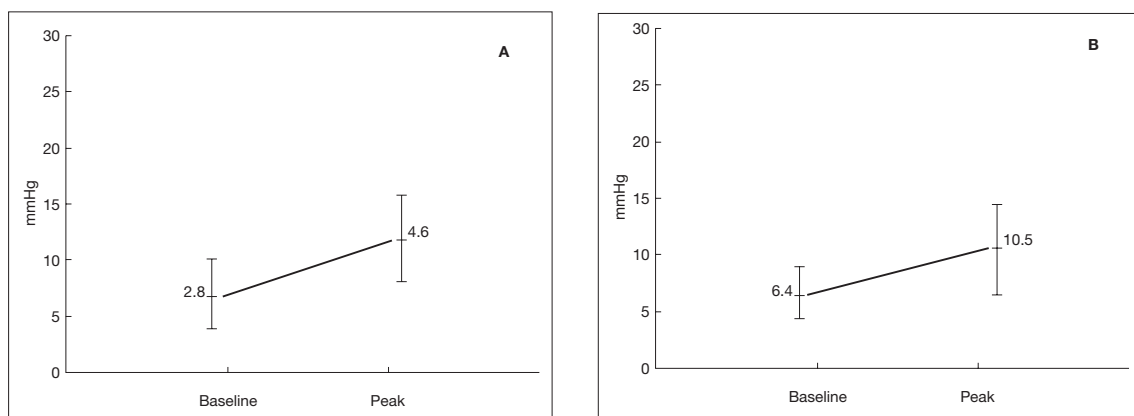
One of the main concerns which have been raised regarding the edge-to-edge technique has been its potential restrictive effect at rest and during exercise. Over the years, however, it has been demonstrated that functional mitral stenosis does not develop after edge-to-edge repair either at baseline or under exercise. Frapier and coworkers (19) compared patients operated on either by Carpentier's techniques or by the edge-to-edge repair. Rest and exercise echocardiogram along with cardiorespiratory testing with maximal oxygen uptake were performed. At baseline, the mean mitral valve area was 2.5 cm<sup>2</sup> after the edge-to-edge and 2.9 cm<sup>2</sup> following classic mitral repair techniques (p = 0.0018). How-

ever, despite the higher mitral valve area reduction, the edge-to-edge technique did not induce more transvalvular gradients than classical Carpentier's repair. Indeed, mean mitral gradients at rest were not significantly different between two groups being 3.8 mmHg in the edge-to-edge and 3.3 mmHg in the classic techniques group, respectively. Moreover, at peak exercise, increase of the mitral gradient and maximum oxygen uptake (VO<sub>2</sub> max) was comparable between two groups. This shows that the edge-to-edge repair is no more restrictive at peak exercise than classic repairs and provides the same efficiency on mitral regurgitation reduction and the same exercise tolerance than Carpentier's techniques. In our Institution we measured the gradients at rest across the mitral valve after edge-to-edge repair since the beginning of our experience. Both immediately after surgery and at follow-up they have been very low with no evidence of mitral stenosis (20). Moreover, an exercise echocardiographic study was specifically designed and performed to assess if the edge-to-edge mitral repair could be a limiting factor for exercise tolerance. Thirty patients previously submitted to double orifice mitral valve repair, underwent exercise echocardiography (10 watt per minute). A ring an-

nuloplasty was present in 28 of them (93%). At peak of the stress heart rate, systolic blood pressure and stroke volume significantly increased showing a physiologic behaviour of the mitral valve. The mean mitral valve gradient ( $2.8 \pm 1.3$  mmHg vs  $4.6 \pm 1.9$  mmHg,  $p < 0.00001$ ), maximum mitral valve gradient ( $6.4 \pm 2.8$  mmHg vs  $10.5 \pm 4.6$  mmHg,  $p < 0.00002$ ) and systolic pulmonary artery pressure ( $22.8 \pm 6.1$  mmHg vs  $28.2 \pm 9.9$  mmHg,  $p < 0.001$ ) increased but not until pathologic levels. Planimetric valve area increased significantly ( $3.2 \pm 0.6$  cm<sup>2</sup> vs  $4.3 \pm 0.7$  cm<sup>2</sup>,  $p < 0.00001$ ) (Figures 5-7) (21). These data clearly demonstrate that artificially created double orifice valves follow a physiologic behavior during exercise with a good valvular reserve in response to the increased cardiac output, a mean transmitral gradient which remains below 5 mmHg and a pulmonary pressure which does not increase up to pathologic levels.

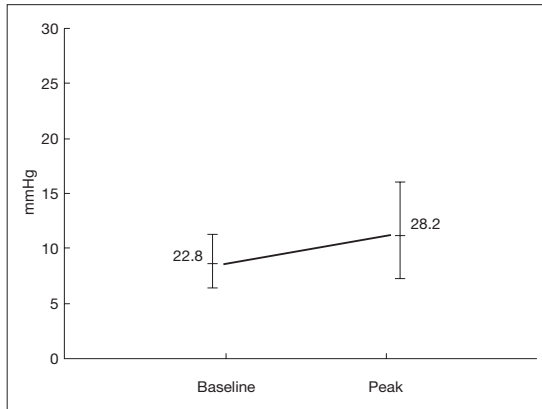
#### *Percutaneous edge-to-edge mitral valve repair*

Catheter adaptations of the edge-to-edge technique have recently enabled mitral valve repair to be performed using endovascular techniques and thus opening the possibility of nonsurgical treatment of mi-

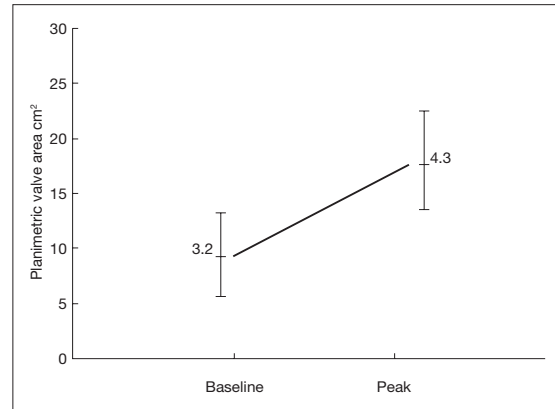


**Figure 5**

Response of mean (A) and maximum (B) mitral gradient to exercise after edge-to-edge repair.



**Figure 6**  
*Exercise-induced change in systolic pulmonary artery pressure after edge-to-edge repair.*

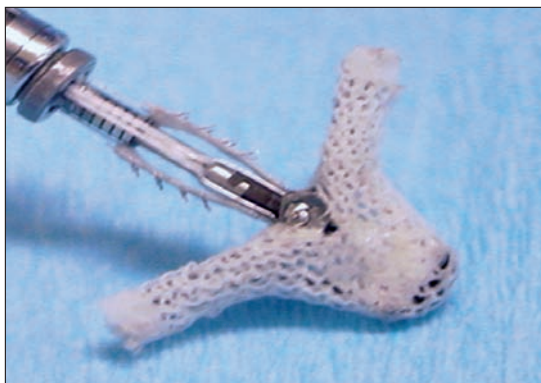

**Figure 7**  
*Exercise-induced change in planimetric mitral valve area after edge-to-edge repair.*

tral regurgitation. The devices simulating surgical edge-to-edge using a percutaneous approach with a transeptal puncture include the MitraClip (Evalve, Menlo Park, CA, USA) and the Mobius II leaflet repair system (Edwards Lifesciences).

The MitraClip (*Figure 8*) is a polyester-covered device with two arms which are able to engage the mitral leaflets. After feasibility studies, the phase I clinical trial (EVEREST I) has been completed and has demonstrated the efficacy of the device (22). The phase II clinical trial with randomization against surgical repair is ongoing. The Mobius II

is also a percutaneous edge-to-edge device which uses a surgical suture to realize anterior and posterior leaflet approximation. In an acute animal model the edge-to-edge repair was performed with this device but further development of the system has been halted. At present selected cases of functional and degenerative mitral regurgitation can be treated percutaneously with the MitraClip although a wider application of this therapeutic option is likely to take place when reliable systems to perform concomitant mitral annuloplasty will become available.



**Figure 8**  
*MitraClip (Evalve, Menlo Park, CA, USA).*

## CONCLUSIONS

The introduction of the edge-to-edge technique has provided an additional contribution to the treatment of mitral regurgitation. Simplicity, reliability and effectiveness are the main advantages of the edge-to-edge technique and have led to its increasing widespread application in the surgical community and to its adoption by a percutaneous approach.

*There is no conflict of interest.*

REFERENCES

1. Yun KL, Miller DC. Mitral valve repair versus replacement. *Cardiol Clin* 1991; 9: 315-327.
2. Olson LJ, Subramanian R, Ackermann DM, et al. Surgical pathology of the mitral valve: a study of 712 cases spanning 21 years. *Mayo Clin Proc* 1987; 62: 22-34.
3. Gillinov AM, Cosgrove DM, Blackstone EH, et al. Durability of mitral valve repair for degenerative disease. *J Thorac Cardiovasc Surg* 1998; 111: 734-743.
4. Braunberger E, Deloche A, Berrebi A, et al. Very long-term results (more than 20 years) of valve repair with Carpentier's techniques in nonrheumatic mitral valve insufficiency. *Circulation* 2001; 104: S8-S11.
5. Mohty D, Orszulak TA, Schaff HV, et al. Very long-term survival and durability of mitral valve repair for mitral valve prolapse. *Circulation* 2001; 104: 1-7.
6. Flameng W, Herijgers P, Bogaerts K, et al. Recurrence of mitral valve regurgitation after mitral valve repair in degenerative valve disease. *Circulation* 2003; 107: 1609-1613.
7. Maisano F, Schreuder JJ, Oppizzi M, et al. The double-orifice technique as a standardized approach to treat mitral regurgitation due to severe myxomatous disease: surgical technique. *Eur J Cardiothorac Surg* 2000; 17: 201-205.
8. De Bonis M, Lorusso R, Lapenna E, et al. Similar long-term results of mitral valve repair for anterior compared with posterior leaflet prolapse. *J Thorac Cardiovasc Surg.* 2006; 131: 364-370.
9. Gillinov AM, Shortt KG, Cosgrove DM 3<sup>rd</sup>. Commissural closure for repair of mitral commissural prolapse. *Ann Thorac Surg* 2005; 80: 1135-1136.
10. Lapenna E, De Bonis M, Sorrentino F, et al. Commissural closure for the treatment of commissural mitral valve prolapse or flail. *J Heart Valve Dis* 2008; 17: 261-266.
11. Bhudia SK, McCarthy PM, Smedira NG, et al. Edge-to-edge (Alfieri) mitral repair: results in diverse clinical settings. *Ann Thorac Surg.* 2004; 77: 1598-1606.
12. De Bonis M, Lapenna E, La Canna G, et al. Mitral valve repair for functional mitral regurgitation in end-stage dilated cardiomyopathy: the role of the "edge-to-edge" technique. *Circulation* 2005; 112: S402-S408.
13. Gatti G, Cardu G, Trane R, et al. The edge-to-edge technique as a trick to rescue an imperfect mitral valve repair. *Eur J Cardiothorac Surg* 2002; 22: 817-820.
14. Brinster DR, Unic D, D'Ambra MN, et al. Mid-term Results of the Edge-to-Edge Technique for Complex Mitral Valve Repair. *Ann Thorac Surg* 2006; 81: 1612-1617.
15. Mascagni R, Al Attar N, Lamarra M, et al. Edge-to-edge technique to treat post-mitral valve repair systolic anterior motion and left ventricular outflow tract obstruction. *Ann Thorac Surg* 2005; 79: 471-473.
16. Lapenna E, Torracca L, De Bonis M, et al. Minimally invasive mitral valve repair in the context of Barlow's disease. *Ann Thorac Surg.* 2005; 79: 1496-1499.
17. Alfieri O, Maisano F, De Bonis M, et al. The double-orifice technique in mitral valve repair: a simple solution for complex problems. *J Thorac Cardiovasc Surg* 2001; 122: 674-681.
18. Maisano F, Redaelli A, Pennati G, et al. The hemodynamic effects of double-orifice valve repair for mitral regurgitation: a 3D computational model. *Eur J Cardiothorac Surg* 1999; 15: 419-425.
19. Frapier JM, Sportouch C, Rauzy V, et al. Mitral valve repair by Alfieri's technique does not limit exercise tolerance more than Carpentier's correction. *Eur J Cardiothorac Surg* 2006; 29: 1020-1025.
20. Maisano F, Torracca L, Oppizzi M, et al. The edge-to-edge technique: a simplified method to correct mitral insufficiency. *Eur J Cardiothorac Surg* 1998; 13: 240-245.
21. Agricola E, Maisano F, Oppizzi M, et al. Mitral valve reserve in double-orifice technique: an exercise echocardiographic study. *J Heart Valve Dis* 2002; 11: 637-643.
22. Silvestry FE, Rodriguez LL, Herrmann HC, et al. Echocardiographic guidance and assessment of percutaneous repair for mitral regurgitation with the Evalve MitraClip: lessons learned from EVEREST I. *J Am Soc Echocardiogr* 2007; 20: 1131-1140.