

# Anomalies and variant anatomy of the aorta and the supra-aortic vessels: additional challenges met by hybrid procedures

F. Setacci, P. Sirignano, G. de Donato, E. Chisci, G. Galzerano, C. Setacci

*Department of Surgery, Vascular and Endovascular Surgery Unit, University of Siena, Siena, Italy*

## ABSTRACT

**Introduction** - Endovascular or hybrid approach to the aortic arch aneurysms is nowadays an appealing solution for selected patients. Aim of this retrospective study is to evaluate the technical and clinical success recorded in complex anatomical settings of endografting.

**Methods** - Between December 2004 and December 2008, 73 patients were treated with a stent-graft for thoracic aorta aneurysms at our Vascular and Endovascular Surgery center, or in other Italian Centers by our Vascular Surgeon as Proctor. The aortic arch was involved in 31 cases. Four cases of bovine arch, three aberrant right subclavian artery and one case of isolated origin of all the supra-aortic trunks (6 vessels) were recorded. Technical success, procedural planning time and procedural time, stroke and paraplegia incidences were analyzed in terms of difference between “normal” or “complex” arches.

**Results** - Technical success was achieved in all cases. Complex anatomy of the arch and the supra-aortic trunks increased the technical difficulty of endovascular exclusion of the aneurysm and required more often complex debranching of the supra-aortic vessel necessary to obtain an adequate landing zone and to preserve the brain and spinal cord perfusion. We observed one stroke in complex arches procedures and two strokes (one of them fatal) in normal arch procedures. No cases of paraplegia were observed.

**Conclusions** - In our experience complex anatomy of the arch did not represent a predictive factor in term of peri-procedural major neurological adverse events.

**Keywords:** *Vascular surgery, Aortic arch, Endovascular, Hybrid, Stroke.*

## INTRODUCTION

Endovascular treatment of thoracic aorta and aortic arch disease is an exciting frontier for catheter based stent-graft technology. Beyond the initial report by Volodos et al. (1), the pioneering work by Dake et al did the most to stimulate the evolutionary developments and growing interest that have taken place over the past several years (2-4).

Data are beginning to accumulate but much remains unclear or unknown in terms of procedural strategies, technical results and early and mid-term outcome (5-7).

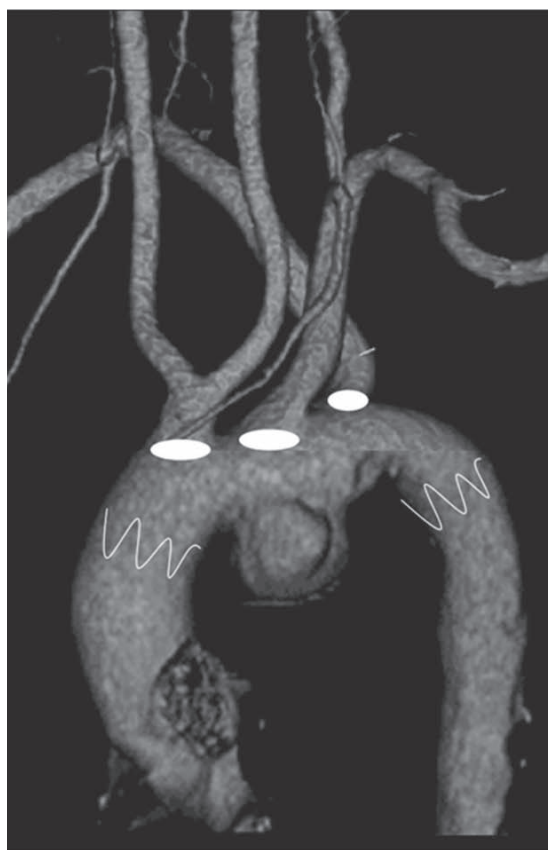The technical challenges of stent graft deployment, such as proximity to the great vessels and arch tortuosity, have been and remain a focus of device engineering. More recently, repair of aortic arch aneurysms was accomplished using both ‘hybrid’ (open and endovascular) and totally endovascular techniques.

Lengthening the branchless descending thoracic aorta is becoming an established and accepted strategy for expanding the applicability of stent-graft repair. The aortic

*Corresponding author:*  
 Francesco Setacci  
 Department of Surgery  
 Vascular and Endovascular Surgery Unit  
 University of Siena, Siena, Italy  
 E-mail: setacci@unisi.it

arch anatomy can play a significant role in this specific procedure, and operators deal with a variety of situations that sporadically challenge routine practice of vascular surgeons. The final anatomical configuration of the aortic root is closely linked to the embryological development of the aortic arch. The development of the aortic arch may produce numerous variations.

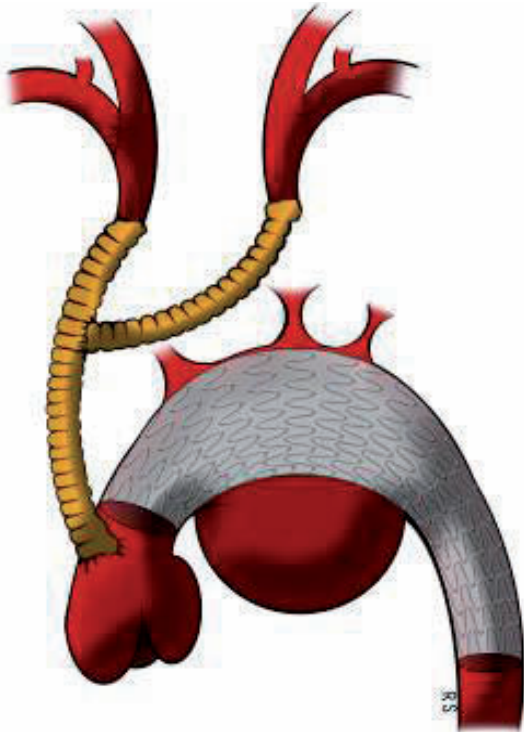
Aortic arch anatomy can be classified as Type I (all supra-aortic vessels originate at the same level in a straight line), Type II (innominate and left common carotid arteries originate below the left subclavian artery) and Type III (all supra-aortic vessels originate below the straight line, the angle between vessel origin and aortic arch is acute).



**Figure 1** - A complex case.

Complex arch anatomy such as arch elongation, diffuse vessel's calcification or anomalies of the origin of supra-aortic vessels increases technical difficulties during aneurysms exclusion (*Figure 1*). Aortic arch anomalies have been classified by various systems (8, 9) some involving as many as 32 categories. There are five broad groups of aortic arch anomalies relevant to the vascular surgeons: double aortic arch, left aortic arch, right aortic arch, cervical aortic arch, carotid anomalies. The most common anomaly is an aberrant right subclavian artery, sometimes referred to as a 'ring', which is present in 0.5 % of individuals. The right common carotid artery and subclavian artery may, also, arise directly from the aortic arch, with the absence of a brachiocephalic trunk.

Common carotid agenesis is rare. One frequent anomaly is the independent origin of the left vertebral artery directly from the aortic arch. Another common anatomical situation (approximately 10 % of cases) is the so-called "bovine-arch" where the left common carotid artery takes origin from the brachiocephalic trunk. This is a clear disadvantage during carotid stenting, but may represent an advantage during thoracic endovascular aneurysms repair (TEVAR). Edward describes three main types of right-sided aortic arch (10): type I, with mirror-image branching of the major arteries; type II, with an aberrant subclavian artery; and type III, with isolation of the subclavian artery (where the subclavian artery is connected to the pulmonary artery through the *ductus arteriosus*). Ductus arteriosus may be on the left, on the right, or bilateral. Type I represents 59 % of all right aortic arches, type II 39.5 %, and type III 0.8 %. In adulthood, symptoms are more often the result of early atherosclerotic changes of the anomalous vessels, dissection, or aneurysmal dilatation with the compression of surrounding structures.



**Figure 2** - Schematic reconstruction of a total arch debranching.

All these situations could increase the technical difficulty of endovascular exclusion of the aneurysm and make complex debranching of the supra-aortic vessel necessary to

obtain an adequate landing zone and to preserve the brain and spinal cord perfusion (Figure 2).

Aim of these retrospective study was to evaluated if complex arch anatomy or variant of supra-aortic trunks can increase the difficulty and the adverse events rate in case of hybrid exclusion of aortic arch aneurysms.

## MATERIAL AND METHODS

Between December 2004 and December 2008, 73 patients were treated with a stent-graft for thoracic aorta aneurysms at our Vascular and Endovascular Surgery center, or in other Italian Center by our Vascular Surgeon as Proctor. The aortic arch was involved in 31 cases. Exclusion criteria was represented by emergency procedures.

This study included only the second phase of our experience (at the end of our learning curve, started in January 2001).

Our indications for treatment included the presence of maximum diameter  $> 5,5$  cm, or more than twice the diameter of an adjacent nonaneurysmal segment of the thoracic aorta, or documented sac growth of  $> 0,5$  cm over a recent 6 months period.

**Table 1** - Preoperative characteristics.

	Normal Arch (23 patients)	Complex Arch (8 patients)	P
Age, year	73 (66-79)	76 (65.5-83.75)	0.6
Sex (male)	19 (83 %)	7 (87 %)	0.7
Tobacco use	13 (57 %)	5 (62 %)	0.8
Diabetes	7 (30 %)	3 (37 %)	0.7
Hypertensionw	18 (78 %)	6 (75 %)	0.3
Pulmonary Disease	14 (61 %)	3 (38 %)	0.3
Renal Disease	4 (17 %)	1 (13 %)	0.7
Cardiac Disease	12 (52 %)	5 (62 %)	0.02
Cerebrovascular Disease	4 (17 %)	2 (25 %)	0.6
Previous abdominal aortic aneuris repair	5 (22 %)	3 (37 %)	0.4

Data were collected as described in *Table 1*. Demographic variables, clinical data, intra-operative and follow-up data were collected by the operative team in a dedicated computed database. Written informed consent for intervention and study protocol was obtained from all patients after ethical committee approval.

TEVAR procedures, in both group, were performed in the operating theatre under general anaesthesia by skilled vascular surgeons. TEVAR were carried out using self-expandable stents-grafts (Valiant, Medtronic Inc, Santa Rosa, CA, USA and Gore Excluder TAG, WL Gore and Ass., Flagstaff, AZ, USA).

Endovascular exclusion of the aneurysm and supra-aortic vessels debranching were performed in a single stage in all cases of both group.

Before treatment, all patients underwent cerebral computed tomography (CT) scan and careful neurological examination performed by an independent board-certified neurologist. Within 24 hours after the procedure and at the 30-day follow-up, patients with new neurological events underwent another neurological examination performed by the same neurologist. In patients with documented neurological complications we performed a post-procedural cerebral CT.

All patients were treated with acetyl-salicylic acid (ASA) at a mean dosage of 125 mg/die at least 4-5 days before hospital admission for TEVAR.

Graft oversizing 15-20% was based on pre-operative CT scans; intraprocedural aortography was performed in all patients. All the procedures were performed using a portable digital C-arm image intensifier (OEC 9800, Healthcare Inc., Mississauga, ON, USA). The contrast agent used was Iodixanolo (Visipaque, 550mg/ml, Healthcare Inc., Mississauga, ON, USA) and the mean volume given during procedure was

148 ± 62 ml. Cerebrospinal fluid drainage was selectively used in patients with prior abdominal aortic aneurysm repair.

The common femoral artery was used as the access site in 29 cases (91%); two patients (9%) had the device inserted through the common iliac artery. During the procedure weight-adjusted (70 U/kg) heparin was administered and repeated as necessary to maintain an activated clotting time of 225 to 250 seconds throughout the procedure.

Total aortic debranching was performed in all cases of “zone 0” and in two case of zone “zone 1”. Left subclavian artery was always reimplanted in “zone 2”. All cases of complex arches group underwent to total aortic arch debranching.

The decision to change “zone 1” in “zone 0” was due to the necessity to obtain an adequate landing zone, almost 2,5cm, to avoid proximal endoleak, as reported by others Authors (11). Technical success, procedural planning time, stroke and paraplegia incidences were analyzed in terms of difference between two groups of patient with “normal” (23 patients) or “complex” (8 patients) arches.

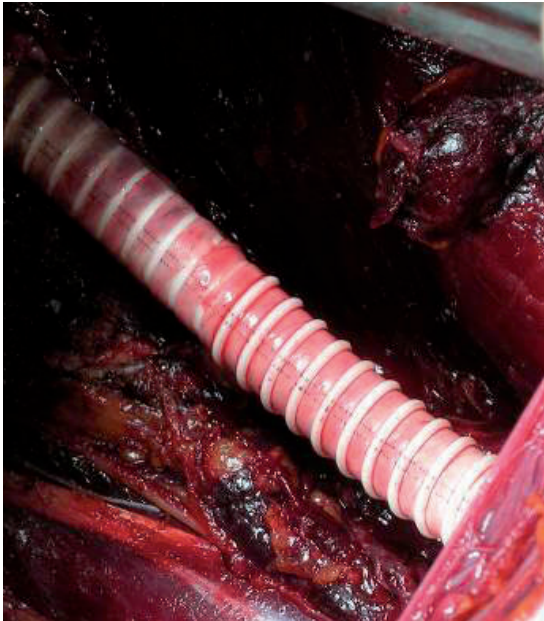
#### *Statistical analysis*

Data are expressed as mean ± standard deviation for the continuous variables or as percentage for the discrete variables. All comparisons between groups were calculated with t Student test or Chi-square test. A p value < 0.05 was considered statistically significant. All the analyses were performed using SPSS software.

## **RESULTS**

Endovascular stent positioning and deployment was technically successful in all cases, with no surgical conversion.

Out of 31 aortic arch cases, 23 had “classic” aortic arch anatomies and eighthead ana-



**Figure 3** - Intraoperative picture the emergent iliaco-femoral by-pass reported in the text.

tomic variants: four cases of bovine arch, three aberrant right subclavian artery and one case of isolated origin of all the supra-aortic trunks (6 vessels).

According to Ishimaru (12) limited to “normal” aortic arch, aortic “zone 0” was involved in four cases, “zone 1” in three cases and “zone 2” in 16 cases. Mean aneurysm diameter was  $64 \pm 8$  mm.

Demographics and clinical features (Ta-

ble 1), were similar ( $p > 0.05$ ) in the two groups

The 30 days mortality rate was 4,3% (1 out of 23) in the normal arch group and 12,5% (1 out of eight) in the complex arch group.

One patient in the normal arch group had an iliac artery rupture during removal of the delivery system (Valiant, Medtronic Inc, Santa Rosa, CA, USA): an in situ stiff guide-wire permitted to treat the patient with endovascular clamping by an aortic occlusion balloon (Reliant, Medtronic Inc, Santa Rosa, CA, USA) and an iliac-femoral by-pass by a synthetic prosthesis (Figure 3).

Peri-operative major complications occurred in four patients (17%) in the normal arch group and in two patients (25%) in the complex arch group (Table 2).

No cases of paraplegia or paraparesis were recorded. Length of follow-up ranged from 1 to 48 months, with a mean time of 8,3 months. No patient died during follow-up period. No cases of proximal endoleak were recorded; 2 patient in the normal arch group (8,7%) and one in the complex arch group (12,5%) had a distal endoleak, due to distal neck dilatation. In all cases the endoleak was sealed by implanting an additional stent-graft; these additional procedures were performed always with cerebrospinal fluid drainage.

**Table 2** - Results in the different aortic arch anatomies.

	Normal Arch (23 patients)	Complex Arch (8 patients)	P
Proximal Endoleak	0	0	-
Aneurysm Related Death	0	0	-
30 Days Mortality	1 (4,3%)	1 (12,5%)	0.4
Paraparesis/Paraplegia	0	0	-
Stroke	2 (8,6%)	1 (12,5%)	0.8
Renal failure	2 (8,6%)	1 (12,5%)	0.8
Intensive care unit stay	3 (2-3)	3 (2.25-3)	0.3
Length hospital stay	9 (8-10)	8.5 (8-10.75)	0.8

## DISCUSSION

We reported the data of 31 consecutive patients treated with a stent-graft for elective aortic arch aneurysms over a four years period by experienced vascular surgeons. We recorded few complications without differences between the 23 patients with normal arch and those eight patients with complex arch anatomy.

Endovascular treatment represents an exciting new treatment option for many patients with life-threatening thoracic aortic lesions for whom standard surgical reconstruction carries significant or prohibitive risks.

Technical approaches and overall strategies evolved considerably in the recent past.

Numerous reports described the use of these technique for a variety of conditions including degenerative aneurysms, pseudoaneurysms (post-surgical and post-traumatic), aortic transection and Type B dissection, penetrating aortic ulcers and aorto-esophageal and aorto-bronchial fistula (13, 14).

No case of spinal cord ischemia was recorded in this series. This lack of spinal cord ischemic events during TEVAR seems to correspond to the theory that neurological complications after thoracic open surgery are more closely related to the aortic cross-clamping time, hypoperfusion during circulatory arrest and cardiopulmonary by-pass (15, 16). However, spinal cord ischemia is a real problem in this kind of intervention, as previous published by other authors (17,18). Risk factors for this dreaded complication include peri-procedural hypotension, previous or concomitant aortic abdominal aneurysm (AAA) repair and extending endograft coverage of the descending aorta. Some reports demonstrated that cerebro spinal fluid drainage prevent spinal cord ischemia during thoracic AAA open repair (19) and during TEVAR (20, 21). According with these reports, we main-

tained cerebro spinal fluid drainage intra-operatively and 2-3 days post-operatively in all patient at risk.

Cerebral ischemia and stroke have also been reported as a complication of TEVAR in the present case series two patients (8,6 %) in the normal arch group and one (12,5 %) in the complex arch groupsuffered such events. They were likely caused by embolic phenomena from manipulation of the aortic arch during advancement of guide-wire and deployment manoeuvres. Optimal interventional skills and gentle technical execution are paramount requirements for the safe conduct of these procedures.

Despite improved results of open repair of the aortic arch with the aid of selective antegrade cerebral perfusion, complications remain high. Reports of total endovascular treatment of aortic arch with branched stent graft are limited to a few cases with unreported midterm results (22, 23). Different case reports have demonstrated the technical feasibility of complete or partial rerouting of the supraortic branches associated with endovascular treatment of aortic arch pathology, but only a few studies including more than ten cases have been published (24, 25). Complete rerouting of the aortic arch is reported in the literature (25-28) but only Bergeron et al. (29) presented a series of more than ten cases. Transposition of supra-aortic trunks, even in abnormal arch anatomies, is a well tolerated procedure in patients with severe comorbidities and allows to treat a large number of cases.

Management of the left subclavian artery arising from "zone 2" remains a debated issue (7,30). In our practice we revascularized the left subclavian artery in all cases, because other authors (31) observed several complications related to left subclavian artery occlusion.

Limitation. No randomization or case-matching was performed in this cohort of patients and

Complex anatomy of the arch and the supra-aortic trunks increased the technical difficulty of endovascular exclusion of the aneurysm and, required complex debranching of the supra-aortic vessel necessary to obtain an adequate landing zone and to preserve the brain and spinal cord perfusion. In our experience of 31 consecutive patients treated with a stent-graft for elective aortic arch aneurysms over a four years period by experienced vascular surgeons, complex anatomy did not represent a predictive factor in term of peri-procedural major adverse events.

*No conflict of interest acknowledged by the authors*

## REFERENCES

- Volodos NL, Korgovic IP, Troyan VI, et al. Clinical experience of use self-fixing synthetics prostheses for remote endoprosthesis of the thoracic and the abdominal aorta and iliac arteries through the femoral artery and as intraoperative endoprosthesis for aorta reconstruction. *Vasa* 1991; 33: 93-95.
- Dake MD, Miller DC, Semba CP et al. Transluminal placement of endovascular stent-grafts for the treatment of the descending thoracic aortic aneurysms. *N Eng J Med* 1994; 33: 1729-1734.
- Dake MD, Miller DC, Mitchell RS et al. The first generation of endovascular stent-grafts for patients with descending thoracic aorta aneurysms. *J Thorac Cardiovasc Surg* 1998; 116: 689-704.
- Fann JJ, Miller DC. Endovascular treatment for descending thoracic aorta aneurysms and dissection. *Sur Clin North Am* 1999; 79: 551-574.
- Greenbergh RK, Resch T, Nyman U et al. Endovascular repair of descending thoracic aortic aneurysms: an early experience with immediate-term follow-up. *J Vasc Surg* 2000; 31: 147-156.
- White RA, Donayre CE, Walet I et al. Endovascular exclusion of descending thoracic aortic aneurysms and chronic dissections: initial clinical results with the AneuRx device. *J Vasc Surg* 2001; 35: 927-934.
- Criado FJ, Clark NS, Barnatan MF. Stent-graft repair in the aortic arch and descending thoracic aorta: a 4 years experience. *J Vasc Surg* 2002; 36: 1121-1128.
- Stewart JR, Kincaid OW, Edwards JE. An atlas of vascular rings and related malformations of the aortic arch system. Springfield (IL): Charles C. Thomas; 1964; 53.
- Edwards JE. Congenital malformations of the heart and great vessels. Section H. Malformations of the thoracic aorta. In: Gould SE, editor. *Pathology of the heart*. 2nd ed. Springfield (IL): Charles C. Thomas 1960; 391-462.
- Edwards JE. Anomalies of the derivatives of the aortic arch system. *Med Clin N Am* 1948; 32: 925-948.
- Melissano G, Civilini E, Bertoglio L et al. Results of endografting of the aortic arch in different landing zones. *Eur J Vasc Endovasc Surg* 2007;33:561-566
- Mitchell RS, Ishimaru S, Ehrlich MP, et al. First International Summit on Thoracic Aortic Endografting: roundtable on thoracic aortic dissection as an indication for endografting. *J Endovasc Ther* 2002; 9: 98-105.
- Nienaber CA, Fattori R, Lund G et al. Nonsurgical reconstruction of thoracic aortic dissection by stent-graft placement. *N Eng J Med* 1999; 340: 1539-1545.
- Coselli JS, Plestis KA, La Francesca S, et al. Results of contemporary surgical treatment of descending thoracic aortic aneurysms: experience in 198 patients. *Ann Vasc Surg* 2003; 17: 185-191.
- Biglioli P, Spirito R, Porqueddu M, et al. Quick, simple clamping technique in descending thoracic aortic aneurysm repair. *Ann Thorac Surg* 1999; 67: 1038-1043.
- Maniar HS, Sundt TM 3rd, Prasad SM, et al. Delayed paraplegia after thoracic and thoracoabdominal aneurysm repair: a continuing risk. *Ann Thorac Surg* 2003; 75: 113-119.
- Gravereaux EC, Faries PL, Burks JA, et al. Risk of spinal cord ischemia after endograft repair of thoracic aneurysms. *J Vasc Surg* 2001; 34: 997-1003.
- Kasirajan K, Dolmatch B, Ouriel F, et al. Delayed onset of ascending paralysis after thoracic aortic stent-graft deployment. *J Vasc Surg* 2000; 31: 196-199.
- Coselli JS, LeMaire SA, Koksoy C, et al. Cerebrospinal fluid drainage reduces paraplegia after thoracoabdominal aneurysms repair: results of a randomized controlled trial. *J Vasc Surg* 2002; 35: 631-639.
- Tiesenhansen K, Amann W, Koch G, et al. Cerebrospinal fluid drainage to reverse paraplegia after endovascular thoracic aortic aneurysms repair. *J Endovasc Ther* 2000; 7: 132-135.
- Ortiz-Gomez JR, Gonzalez-Solis FJ, Fernandez-Alonso L, et al. Reversal of acute paraplegia with

- cerebrospinal fluid drainage after endovascular thoracic aortic aneurysm repair. *Anesthesiology* 2001; 95: 1288-1289.
22. Chuter TA, Schneider DB, Reilly LM, et al. Modular branched stent graft for endovascular repair of aortic arch aneurysm and dissection. *J Vasc Surg* 2003; 38: 859-863.
  23. Saito N, Kimura T, Odashiro K, et al. Feasibility of the Inoue single-branched stent-graft implantation for thoracic aortic aneurysm or dissection involving the left subclavian artery: short- to medium-term results in 17 patients. *J Vasc Surg* 2005; 41: 206-212
  24. Melissano G, Civilini E, Bertoglio L, et al. Endovascular treatment of aortic arch aneurysms. *Eur J Vasc Endovasc Surg* 2005; 29: 131-138.
  25. Czerny M, Gottardi R, Zimpfer D, et al. Transposition of the supraaortic branches for extended endovascular arch repair. *Eur J Cardiothorac Surg* 2006; 29: 709-713.
  26. Schumacher H, Bockler D, Bardenheuer H, et al. Endovascular aortic arch reconstruction with supra-aortic transposition for symptomatic contained rupture and dissection: early experience in 8 high-risk patients. *J Endovasc Ther* 2003; 10: 1066-1074.
  27. Zhou W, Reardon ME, Peden EK, et al. Endovascular repair of a proximal aortic arch aneurysm: a novel approach of supra-aortic debranching with antegrade endograft deployment via an anterior thoracotomy approach. *J Vasc Surg* 2006; 43: 1045-1048.
  28. Gottardi R, Seitelberger R, Zimpfer D, et al. An alternative approach in treating an aortic arch aneurysm with an anatomic variant by supraaortic reconstruction and stent-graft placement. *J Vasc Surg* 2005; 42: 357-360.
  29. Bergeron P, Mangialardi N, Costa P, et al. Great vessel management for endovascular exclusion of aortic arch aneurysms and dissections. *Eur J Vasc Endovasc Surg* 2006; 32: 38-45.
  30. Gorich J, Asquan Y, Seifarth H, et al. Initial experience with intentional stent-graft coverage of the subclavian artery during endovascular thoracic aortic repairs. *J Endovasc Ther* 2002; 9: 39-43.
  31. Peterson BG, Eskandari MK, Gleason TG, et al. Utility of left subclavian artery revascularization in association with endoluminal repair of acute and chronic thoracic aortic pathology. *J Vasc Surg* 2006; 43: 433-439.